

LI Yuan, WANG Changqiu, LU Anhuai, LI Yan, LI Kang, YANG Chongqing. The Characterization of Aortic Valve Calcification at Different Stage of Disease. *Acta Geologica Sinica* (English Edition), 91(supp. 1): 163-163.

The Characterization of Aortic Valve Calcification at Different Stage of Disease

LI Yuan¹, WANG Changqiu^{1*}, LU Anhuai¹, LI Yan¹, LI Kang², YANG Chongqing³

¹ Key Laboratory of Orogenic Belts and Crustal Evolution, MOE, Beijing Key Laboratory of Mineral Environmental Function, School of Earth and Space Sciences, Peking University, Beijing 100871, China

² Department of Cardiology, Beijing Hospital, Beijing 100730, China

³ Department of Pathology, Beijing Hospital, Beijing 100730, China

Cardiac valve calcification is a common disease, especially among the elderly. Calcification can affect valve function and cause heart failure and sudden death (Adler et al., 2002). Aortic valve calcification is also related to arteriosclerosis and coronary heart disease (Rashedi et al., 2015). However, the origin of valve calcification is still unclear. This study characterized the samples with different level of calcification and discussed the development of calcification through the progression of disease.

Samples were acquired from Beijing Hospital, including seven aortic valve thickening samples (without notable calcification) and nine aortic valve with notable calcification. The study was approved by both the patients and the ethics committee of Beijing Hospital. The samples were processed into thin sections and calcification powders for different tests.

Calcification powder was analysed by micro-area synchrotron radiation X-ray powder diffraction (μ -SRXRD) and Micro-FTIR. The XRD pattern of calcification fit perfectly with hydroxyapatite (PDF#01-089-7834). The FTIR spectra detected the existence of CO₃²⁻ group, thus the mineral phase in calcification was identified as carbonate hydroxyapatite.

The aortic valve thickening is an initial stage of calcification, and there were no trace of calcification in the hematoxylin-eosin stained sections. But when observed by SEM, calcification spheres could be seen distributed on the collagen fiber (Fig. 1a). In SEM image of samples with notable calcification. Massive calcification could be seen in the center of the lesion and spherical calcification were next to it (Fig. 1b). The spheres close to massive calcification have a larger average diameter than those were distant from massive calcification. The above SEM observation demonstrate

that the initial form of calcification was calcification sphere. With the progression of disease, spheres gradually grow larger, and eventually developed into massive calcification. The energy dispersive spectrometer (EDS) demonstrate that massive calcification have higher Ca/P(At%) than spherical calcification, and big spheres have higher Ca/P(At%) than small spheres (Fig. 1b), these Ca/P(At%) difference indicate a maturation process during the calcification development.

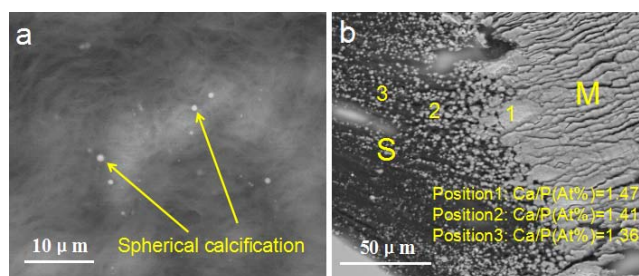


Fig. 1. SEM-BSE images of aortic valve calcification. (a) Spherical calcification (b) The border of massive calcification (M) and spherical calcification (S); The number 1, 2, 3 were the positions of EDS test, the Ca/P(At%) values were marked in the picture.

This study was supported by the National Natural Science Foundation of China (Grant NO. 40972210, 41272048)

References

- Adler, Y., Vaturi, M., Herz, I., Iakobishvili, Z., Toaf, J., Fink, N., Battler, A., Sagie, A., 2002. Nonobstructive aortic valve calcification: A window to significant coronary artery disease. *Atherosclerosis*, 161, 193-197.
- Rashedi N, Otto CM., 2015. Aortic Stenosis: Changing Disease Concepts. *J Cardiovasc Ultrasound*, 23(2): 59-69.

* Corresponding author. E-mail: cqwang@pku.edu.cn